

PARAQUAT-INDUCED HISTOPATHOLOGICAL CHANGES ON THE GILLS, KIDNEY AND LIVER TISSUES OF *ANABAS TESTUDINEUS* (BLOCH 1792)

NOR AZRI-SHAH NORHAN¹, MOHD IHWAN ZAKARIAH¹, NURUL ULFAH KARIM¹, HASSAN MOHD DAUD², ANUR ABDALAH NAGI MELAD³, NOR ASMA HUSNA YUSOFF¹ AND MARINA HASSAN^{1*}

¹Higher Institution Centre of Excellence (HICoE), Institute of Tropical Aquaculture and Fisheries, Universiti Malaysia Terengganu, 21030 Kuala Nerus, Terengganu, Malaysia. ²Department of Veterinary Clinical Studies, Universiti Putra Malaysia, 43400 Serdang, Selangor, Malaysia. ³Department of Biological Science, Faculty of Science, Azzaytuna University, Tarhounah, Libya.

*Corresponding author: marina@umt.edu.my

Submitted final draft: 12 April 2022

Accepted: 18 June 2022

<http://doi.org/10.46754/jssm.2022.08.010>

Abstract: Paraquat is the most widely used herbicide in agricultural activities for land preparation and weed control. Uncontrolled usage and poor waste management will introduce the chemical into the aquatic ecosystem due to agricultural runoff, causing harm to non-targeted aquatic species, especially fish. Therefore, this study was performed to evaluate the histological alterations of the gill, liver and kidney of the freshwater fish *Anabas testudineus*. Fish were exposed to four paraquat concentrations (2.0, 5.0, 12.0 and 15.0 mg/L) for 96 hours in controlled water parameters and without feeding. Following treatment, all fish were pithed and their gills, livers and kidneys were collected. Histopathological analysis with semi-quantitative scoring lesions were performed to determine the severity of the tissue changes in each fish organ. Histopathological changes in the gills after 96 hours of paraquat exposure showed lamella curvature, hyperplasia, edema, blood vessel congestion and necrosis compared with the control group. Histological changes, like degeneration in hepatocytes and necrosis were observed in the livers and kidneys exposed to 2.0-12.0 mg/L of paraquat. Prominent histopathological changes were observed in 15.0 mg/L of paraquat exposure, including nuclear pyknosis and necrosis. Overall, this study demonstrated deleterious effects of paraquat on the tissues of *A. testudineus*. The histopathological changes were proportional to the paraquat concentration and may impair organs' vital functions which in turn affects the fish's health.

Keywords: Fish, herbicides, paraquat, sub-lethal toxicity.

Introduction

The application of pesticides is rapidly expanding around the world, particularly in the agriculture industry, to reduce undesirable plants and increase crop yields. Paraquat (1,1'-dimethyl-4,4'-bipyridinium dichloride) is one of the common herbicides used due to its non-selective and broad spectrum activity in killing weeds and grasses. However, due to their extensive use and the poor management of herbicide spills, they leach into the aquatic environment (Bagheri *et al.*, 2021), thus, becoming a threat to non-targeted aquatic organisms especially fish (Sharma *et al.*, 2019). Fish contaminated by the paraquat herbicide will have toxic accumulations in their bodies which

may affect human health once they consume the fish (Sribanjam *et al.*, 2018). Moreover, herbicide accumulation in aquatic organisms has been known to promptly affect metabolic and reproductive activities, as well as embryonic development (Mussi & Calcaterra, 2010; Orrego *et al.*, 2017) which eventually led to reduced fish productivity (Melvin, 2016). Even in reality, paraquat has disrupted freshwater plankton communities and killed fish three times more than weed (Rosic *et al.*, 2020).

Fish is an important biomarker and is highly sensitive to environmental changes, especially toxicant exposure. The histopathological alterations that occurred in their organs, particularly the gill (Marcon *et al.*, 2016; Soares

et al., 2016), liver (Singh, 2012; Kumar *et al.*, 2016) and kidney (Mangang & Pandey, 2021) will determine the effects of contaminants in aquatic bodies (Yeganeh *et al.*, 2016). A study reported by Badroo *et al.* (2020) showed significant damage caused to the vital organs of *Channa punctatus* following acute exposure to paraquat dichloride. Additionally, Ma *et al.* (2018) revealed the destabilising of fish metabolism, inhibition of antioxidant enzymes and up-regulation of anti-inflammatory enzymes in the livers of fish after being exposed to paraquat for seven days. Ma *et al.* (2014) also discovered changes in inflammatory cytokines, lysozyme activities and histopathological damage in the liver and kidney of the common carp following paraquat exposure. Similarly, histological changes in gourami fish (Banaee *et al.*, 2013) and mitochondrial dysfunction at the early development stage of zebrafish (Wang *et al.*, 2018) were reported in paraquat-exposed fish. Disturbance of gluconeogenesis and glycolysis processes in the fish liver due to paraquat contamination may also disrupt glycogen synthesis and impair fish health (Khanh *et al.*, 2021). In some cases, the interactions of paraquat with other mixture of toxicants in the environment such as cadmium, lead, copper and nanoparticles (Maharajan *et al.*, 2016; Mansouri *et al.*, 2016; 2017; Banaee *et al.*, 2019; Khanh *et al.*, 2021) may increase the toxicity effect to the exposed fish. All these histological changes may affect the vital function of organs (i.e., respiration, metabolic cycles and excretion) which can lead to a decrease in fish health and death.

Climbing perch (*Anabas testudineus*) is indigenous and widely distributed in Southeast Asian countries. This benthic, omnivorous and air-breathing fish is a hardy species, long-lived, easily adapted to high-stock density and in experimental controlled conditions with low stress levels, therefore, serving as the best model of study (Hashim *et al.*, 2015; Khanh *et al.*, 2021). Therefore, the present study aims to investigate the histopathological changes in vital organs like the gill, liver and kidney of *A. testudineus* exposed to acute doses of paraquat for 96 hours.

This outcome may be important for developing knowledge of the fish's condition when areas they inhabit are contaminated with paraquat and also for knowing the histopathological responses of *A. testudineus* at acute doses.

Materials and Methods

Fish Collection and Acclimatisation

Adult *A. testudineus* with a mean body weight of 40.0 ± 11.0 g bought from a local fish farm was transferred to the Institute of Tropical Aquaculture and Fisheries Hatchery, Universiti Malaysia Terengganu from a local fish farm. The fish were acclimatised for 14 days under a natural photoperiod of 12:12 light-dark cycle and fed twice daily with commercial fish pellets. Feeding was interrupted 24 hours before the experiment.

Sub-lethal Toxicity Test

A farmer-grade herbicide paraquat was bought from a local farm agricultural supply shop (PELADANG, Malaysia). The initial concentration of the paraquat stock was 135.59 g/L which was then dissolved to 100 mg/L in double-distilled as a stock solution before being diluted with dechlorinated tap water to obtain the experimental concentrations. Prior to the sub-lethal test, an acute toxicity test was performed which determined the 96-h LC₅₀ of paraquat to be 16.81 mg/L (Norhan *et al.*, 2019). A sub-lethal paraquat toxicity test was conducted for 96 hours with four groups of paraquat concentrations (2.0, 5.0, 12.0 and 15.0 mg/L) and a control (0.0 mg/L). The healthy and acclimatised fish were randomly selected and exposed to the treatments. Each group held 10 *A. testudineus* and the treatments were performed in triplicate. No feeding was conducted during the experiment and water parameters, including pH (7.3-7.5), salinity (27.0-30.2‰), temperature (26.8-27.0°C) and dissolved oxygen (6.5-7.1 mg/L) were maintained and monitored using the YSI multi-parameter probe (YSI Inc., USA). This sub-lethal toxicity test was carried out in a non-renewal static condition (USEPA, 2002).

Histopathological Analysis

At the end of the experiment, all fish were euthanised with the pithing technique and dissected to remove the gills, livers and kidneys. No mortality was recorded in all groups. The gills were fixed in 10% formalin acetic acid (FAA) while the livers and kidneys were fixed in 10% neutral buffered formalin. These tissues were processed by following standard tissue processing procedures (dehydration by alcohol, clearing by xylene and impregnation by wax) and embedded in paraffin wax. The embedded tissues were sectioned into 5 µm thickness using a rotary microtome and stained with haematoxylin and eosin. The prepared slides were examined using the Advance Research Microscope (NIKON Eclipse 80i) and photographed at 400x and 1,000x magnifications. Histopathological changes were observed in the gill, liver and kidney tissues. Tissue changes were assessed via semi-quantitative lesion scoring which are categorised as normal (-), mild (+), moderate (++) and severe (+++) (Stalin *et al.*, 2019).

Results

Histopathology Effects in the Gill, Liver and Kidney of A. testudineus

A. testudineus exposed to sub-lethal paraquat concentrations indicated several tissue changes in the gill, liver and kidney (Table 1). The tissue changes were lamellar epithelial lifting, hyperplasia, edema, blood vessel congestion and necrosis. In both 2.0 and 5.0 mg/L groups, lamellar epithelial lifting, hyperplasia and edema were observed. Severity was increased in paraquat exposure of 12.0 mg/L which caused lamellar fusion whereas 15.0 mg/L resulted in blood vessel congestion and gill necrosis. In the highest exposure group, tissue changes such as edema and hyperplasia increased severely. Simultaneously, lamellar fusion was observed due to increased proliferation of lamellar epithelial cells which fused the adjacent secondary lamellae. The architecture and structural properties of the gill tissue had changed within 96 hours of exposure to paraquat, in comparison to the control group (Figure 1).

Table 1: Semi-quantitative evaluation of histopathological changes in the gill, liver and kidney of *A. testudineus* exposed to paraquat for 96 hours at different concentrations

Organ	Paraquat Concentration (mg/L)/Tissue Changes	0.0 (Control)	2.0	5.0	12.0	15.0
Gill	Lamellar epithelial lifting	-	+	+	++	++
	Hyperplasia	-	+	+	++	+++
	Edema	-	+	+	++	+++
	Blood vessel congestion	-	-	-	-	++
	Necrosis	-	-	-	-	+
Liver	Degeneration	-	+	++	++	+++
	Necrosis	-	-	-	++	+++
	Nuclear pyknosis	-	-	-	-	+++
	Haemorrhage	-	-	-	-	+
Kidney	Degeneration	-	+	++	++	+++
	Hyperplasia	-	-	-	+	++
	Nuclear pyknosis	-	-	-	++	+++
	Necrosis	-	-	-	++	++

Note: - = None (0%), + = Mild (<10%), ++ = Moderate (10-50%), +++ = Severe (>50%)

The liver showed several tissue changes after 96 hours of paraquat exposure. Normal hepatocytes were structurally arranged, with a central and spherical-shaped nucleus after 96 hours of paraquat exposure in the control group. However, hepatocytes showed hydropic degeneration in the 2.0 and 5.0 mg/L paraquat exposure group which was more severe in the 5.0 mg/L group. At 12.0 mg/L exposure, there was necrosis and hydropic degeneration of the hepatocytes. The exposure to paraquat at 15.0 mg/L caused pyknosis, haemorrhage, hydropic degeneration and necrosis. Histological sections of the liver in both the control and paraquat-exposed groups are depicted in Figure 2.

Several tissue changes were found in kidneys exposed to paraquat for 96 hours (Table 1, Figure 3). Fish exposed to 2.0 and 5.0 mg/L of paraquat developed mild to moderate hydropic degeneration of tubular epithelial cells. Mild haematopoietic cell hyperplasia with moderate nuclear pyknosis and tubular epithelial necrosis were observed at 12.0 mg/L of paraquat

exposure. All tissue changes in the kidneys were found to be severe after 15.0 mg/L of paraquat exposure. No tissue changes were observed in the control group.

Discussion

This present study was conducted to report paraquat toxicosis with regards to histopathological alterations in *A. testudineus* under laboratory conditions. The fish gill is a multi-function organ that is directly exposed to its environment and is an excellent model for the study of fish diseases and toxicology, which focus on gill alterations and responses (Samanta et al., 2018). In this study, *A. testudineus* groups exposed to paraquat herbicide exhibited lamellar epithelial lifting, hyperplasia and fusion in their gills. The lamellar epithelial lifting is the separation between the epithelial cells and lacuna in the secondary lamella. This separation increases oxygen diffusion distances between the epithelial cell and lacuna (Maharajan et al., 2016). Meanwhile, lamellar epithelial hyperplasia is a

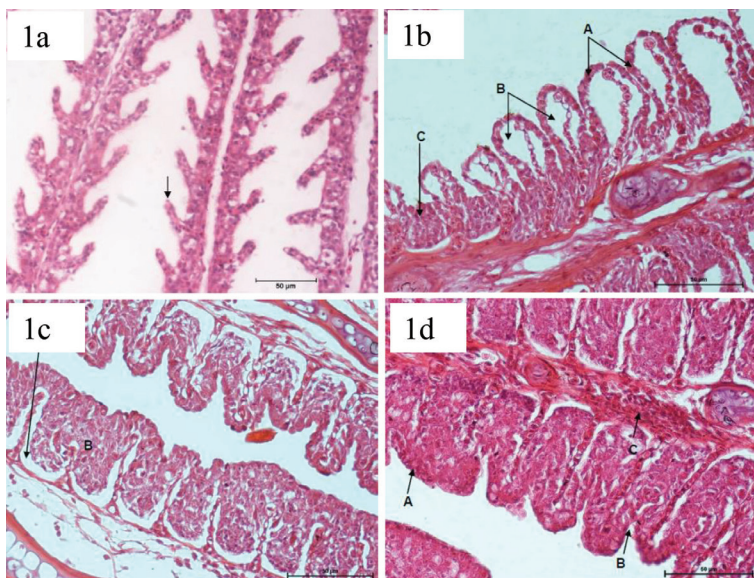


Figure 1: The gills of *A. testudineus* exposed to different concentrations of paraquat: (1a) Control (0.0 mg/L) arrow shows the normal structures of secondary gill lamellae, (1b) 12 mg/L of paraquat, lamellar epithelial lifting (A), edema (B), lamellar epithelium hyperplasia and fusion (C), (1c) 15 mg/L of paraquat, edema (A), lamellar epithelial hyperplasia and fusion (B), (1d) 15 mg/L of paraquat, lamellar epithelial hyperplasia and fully secondary lamellar fusion (A), partially secondary lamellar fusion (B) and congested of blood vessel (C). H&E: 400x magnification

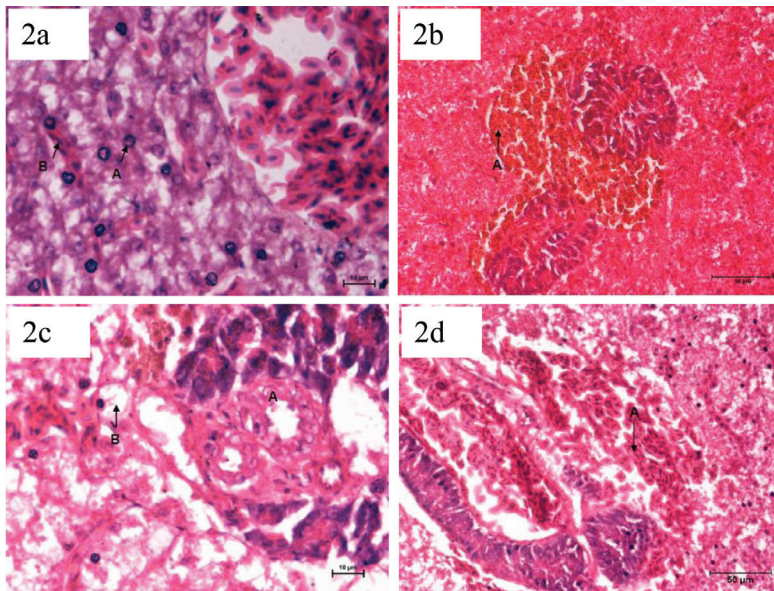


Figure 2: The livers of *A. testudineus* after exposure to different paraquat concentrations. (2a) Control (0.0 mg/L of paraquat), hepatocytes with rounded nuclei (A) and erythrocytes in liver sinusoid (B), (2b) 5 mg/L of paraquat, a pigmented macrophage aggregation around hepatopancreas (A), (2c) 12 mg/L of paraquat, hepatopancreas disintegration (A) and hydropic degeneration (B) and (2d) 15 mg/L of paraquat, haemorrhage (A). H&E: 1,000x magnification

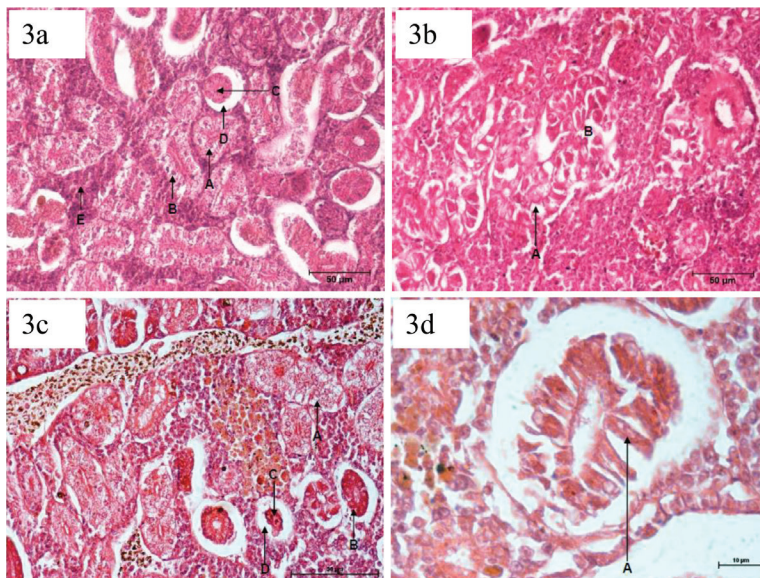


Figure 3: The kidneys of *A. testudineus* after exposure to different paraquat concentrations. (3a) Control (0.0 mg/L of paraquat), normal appearance of distal tubule (A), proximal tubule (B), glomerulus (C), Bowman's space (D) and hematopoietic tissue (E), (3b) 12 mg/L of paraquat, tubular epithelial hydropic degenerations and loss of tubule lumen (A), tubular necrosis (B), (3c) 15 mg/L of paraquat, hydropic degeneration of tubule epithelium and loss of tubule lumen (A), tubule shrinkage (B), glomerulus shrinkage (C), Bowman's space increase (D) and (3d) 15 mg/L of paraquat, tubule necrosis (A). H&E: 1,000x of magnification

high epithelial proliferation activity that results in the fusion of adjacent secondary lamellae, which increases the epithelium thickness, decreasing gill surface area and reducing the functional lamellae. Generally, these gill alterations act as a defensive mechanism that minimises toxicant from getting into the fish's circulatory system which may impair the gas exchange process and other gill functions (Flores-Lopes & Thomaz, 2011).

Another defensive response against a toxic environment found in this study was mucous secretion in the gills. This sign was reported previously by Singh *et al.* (2021) who stated that once excessive mucous secretion is exhibited, high mucous cell proliferation will occur (Carvalho *et al.*, 2020) in order to provide an additional layer of protection from the toxic environment as documented in *Oreochromis* sp. and *Rhamdia quelen* (Hassan *et al.*, 2013; Brum *et al.*, 2014). Other alterations present in the gill structure (i.e., epithelial necrosis, haemorrhage and rupture of gill epithelium) are considered direct deleterious effects of the irritants. Epithelial necrosis was observed at 15.0 mg/L of paraquat exposure which was similarly reported in *Lates calcarifer* exposed to copper metal (Maharajan *et al.*, 2016). Congested blood capillaries in *A. testudineus* were caused by erythrocyte increment in lamellar blood vessels and led to a weak pillar cell structure. The weakened epithelial and pillar cells will collapse and conclusively leads to haemorrhage which eventually led to severe blood loss and decreased oxygen transfer to other tissues (Barja-Fernández *et al.*, 2013).

Liver is a detoxification organ that serves as a biomarker for environmental quality (Gartner *et al.*, 2014). In the present study, paraquat exposure caused several regressive changes in *A. testudineus* liver including hepatocyte degeneration, necrosis and nuclear pyknosis which have also been previously observed in *A. testudineus* livers exposed to agrochemical herbicide "Almix" (Samanta *et al.*, 2018). Alterations were observed at the lowest paraquat

concentration and became more severe with increased concentration. Mansouri *et al.* (2015) found similar results when the severity of damage caused by cobalt nanoparticles in the gills of zebrafish increased as toxicant concentrations increased. In this study, the excessive paraquat in cells can damage intracellular elements such as the mitochondria and peroxisome membrane, and trigger the formation of reactive oxygen species (ROS). These ROS (i.e., hydrogen peroxide and hydroxyl radicals) will cause severe cell damage and necrosis (Chen *et al.*, 2021) and destroy lipid peroxidation and DNA fragmentation as the final consequences (Ayanda *et al.*, 2021). Another tissue alteration caused by ROS's cytotoxic properties is hydropic degeneration. Hydropic degeneration is an early indication of cellular degeneration in response to cell injury. The high intake and accumulation of fluid in degenerated cells were due to the impairment of osmotic homeostasis (Wallig & Janovitz, 2013). Prolonged and intensified toxicant exposure will aggravate the severity of this tissue alteration and demote hepatic function and its structural arrangement.

Kidney is another organ susceptible to damage by toxicants in water as it receives blood from the gills and acts as an excretory organ to eliminate waste products of metabolism and detoxification (Jeziarska & Witeska, 2006). Short-term exposure to paraquat results in renal alterations, including hydropic degeneration as well as architectural and structural alterations to the glomerular and Bowman's capsule space, and distal and proximal convoluted tubules. These alterations are a hard indication of toxicity stress (Yeganeh *et al.*, 2016). Necrotic tissue development and glomerular shrinkage were observed in *A. testudineus* kidneys exposed to 12.0-15.0 mg/L of paraquat which may promote tissue regeneration and impair kidney functions. In addition, this interrupted glomerular filtration activity and excretion impairment may also lead to toxicant accumulation in the kidney organ and failure of its function (Palermo *et al.*, 2015).

Conclusion

This study clearly showed that paraquat causes several histopathological alterations in the gill, liver and kidney of *A. testudineus* after 96 hours of exposure. The severity increases as the paraquat concentrations increase with 15.0 mg/L causing the most tissue changes in all fish organs. It can be concluded that paraquat is toxic to fish and this finding may be useful in determining the health status of the entire aquatic ecosystem.

Acknowledgements

We thank the Institute of Tropical Aquaculture and Fisheries, Universiti Malaysia Terengganu for providing the facilities for this study. This research has been funded by the Ministry of Higher Education under the grant Research Acculturation Collaborative Effort (RACE) - grant number 56012.

References

- Ayanda, O. I., Tolulope, A., & Oniye, S. J. (2021). Mutagenicity and genotoxicity in juvenile African catfish, *Clarias gariepinus* exposed to formulations of glyphosate and paraquat. *Science Progress*, 104(2), 1-15.
- Badroo, I. A., Nandurkar, H.P., & Khanday, A. H. (2020). Toxicological impacts of herbicide paraquat dichloride on histological profile (gills, liver, and kidney) of freshwater fish *Channa punctatus* (Bloch). *Environmental Science and Pollution Research*, 27, 39054-39067.
- Bagheri, A., Emami, N., & Damalas, C. A. (2021). Farmers' behavior towards safe pesticide handling: An analysis with the theory of planned behavior. *Science of the Total Environment*, 751, 141709.
- Banaee, M., Davoodi, M. H., & Zoheiri, F. (2013). Histopathological changes induced by paraquat on some tissues of gourami fish (*Trichogaster trichopterus*). *Open Veterinary Journal*, 3(1), 36-42.
- Banaee, M., Tahery, S., Nematdoost, H. B., Shahafve, S., & Vaziriyani, M. (2019). Blood biochemical changes in common carp (*Cyprinus carpio*) upon co-exposure to titanium dioxide nanoparticles and paraquat. *Iranian Journal of Fisheries Sciences*, 18(2), 242-255.
- Barja-Fernández, S., Míguez, J. M., & Álvarez-Otero, R. (2013). Histopathological effects of 2, 2',4,4'-tetrabromodiphenyl ether (BDE-47) in the gills, intestine and liver of turbot (*Psetta maxima*). *Ecotoxicology and Environmental Safety*, 95, 60-68.
- Brum, A., Dotta, G., Roubbedakis, K., Gonçalves, E. L. T., Garcia, L. P., Garcia, P., Scussel, V. M., & Martins, M. L. (2014). Hematological and histopathological changes in silver catfish *Rhamdia quelen* (Siluriformes) exposed to clomazone herbicide in the Madre River, Santa Catarina State, Southern Brazil. *Journal of Environmental Science and Health: Part B*, 49(3), 169-175.
- Carvalho, T. L. A. de B., Do Nascimento, A. A., Gonçalves, C. F. D. S., Dos Santos, M. A. J., & Sales, A. (2020). Assessing the histological changes in fish gills as environmental bioindicators in Paraty and Sepetiba bays in Rio de Janeiro, Brazil. *Latin American Journal of Aquatic Research*, 48(4), 590-601.
- Chen, J., Su, Y., Lin, F., Iqbal, M., Mehmood, K., Zheng, H., & Shi, D. (2021). Effect of paraquat on cytotoxicity involved in oxidative stress and inflammatory reaction: a review of mechanisms and ecological implications. *Ecotoxicology and Environmental Safety*, 224, 112711.
- Flores-Lopes, F., & Thomaz, At. (2011). Histopathologic alterations observed in fish gills as a tool in environmental monitoring. *Brazilian Journal of Biology*, 71(1), 179-188.
- Gartner, L. P., Hiatt, J. L., & Gartner, L. P. (2014). *Color atlas and text of histology*

- (6th ed.). Wolters Kluwer Health/Lippincott Williams & Wilkins.
- Hashim, R., Azlan, M. R. P., Mohd Zainuddin, W. M. A., Jusoh, S. A., & Md Sah, A. S. R. (2015). Fish Distribution and Composition of Kelantan River Systems, Kelantan, Malaysia. *Applied Mechanics and Materials*, 747, 294-297.
- Hassan, M., Zakariah, M. I., Wahab, W., Mohammad, S. D., Idris, N., & Jasmani, S. (2013). Histopathological and behavioral changes in *Oreochromis* sp. after exposure to different salinities. *Journal of Fisheries and Livestock Production*, 1(2), 2-5.
- Jeziarska, B., & Witeska, M. (2006). The metal uptake and accumulation in fish living in polluted waters. In I. Twardowska, H. E. Allen, M. M. Häggblom, & S. Stefaniak (Eds.). *Soil and Water Pollution Monitoring, Protection and Remediation* (Vol. 69, pp. 107-114). Springer Netherlands.
- Khanh, D. N. N., Vy, N. T. T., Phuong, T. H., Nhi, P. T., Thang, N. Q., Sy, D. T., & Phuong, N. T. K. (2021). Effects of cadmium and lead on muscle and liver glycogen levels of Climbing perch (*Anabas testudineus*). *Bulletin of Environmental Contamination and Toxicology*.
- Kumar, N., Ambasankar, K., Krishnani, K. K., Gupta, S. K., Bhushan, S., & Minhas, P. S. (2016). Acute toxicity, biochemical and histopathological responses of endosulfan in *Chanos chanos*. *Ecotoxicology and Environmental Safety*, 131, 79-88.
- Ma, J., Li, X., Li, Y., Li, Y., & Niu, D. (2014). Toxic effects of paraquat on cytokine expression on common carp, *Cyprinus carpio* L. *Journal of Biochemical and Molecular Technology*, 28(11), 501-509.
- Ma, J., Li, Y., Li, W., & Li, X. (2018). Hepatotoxicity of paraquat on common carp (*Cyprinus carpio* L.). *Science of the Total Environment*, 616-617, 889-898.
- Maharajan, A., Kitto, M. R., Paruruckumani, P. S., & Ganapiriyaa, V. (2016). Histopathology biomarker responses in Asian sea bass, *Lates calcarifer* (Bloch) exposed to copper. *The Journal of Basic and Applied Zoology*, 77, 21-30.
- Mangang, Y. A., & Pandey, P. K. (2021). Hemato-biochemical responses and histopathological alterations in the gill and kidney tissues of *Osteobrama belangeri* (Valenciennes, 1844) exposed to different sub-lethal unionized ammonia. *Aquaculture*, 542, 736887.
- Mansouri, B., Maleki, A., Johari, S. A., & Reshahmanish, N. (2015). Effects of cobalt oxide nanoparticles and cobalt ions on gill histopathology of zebrafish (*Danio rerio*). *AACL Bioflux*, 8(3).
- Mansouri, B., Maleki, A., Davari, B., Johari, S. A., Shahmoradi, B., Mohammadi, E., & Shahsavari, S. (2016). Histopathological effects following short-term coexposure of *Cyprinus carpio* to nanoparticles of TiO₂ and CuO. *Environmental Monitoring and Assessment*, 188, 575.
- Mansouri, B., Maleki, A., Johari, S. A., Shahmoradi, B., Mohammadi, E. & Davari, B. (2017). Histopathological effects of copper oxide nanoparticles on the gill and intestine of common carp (*Cyprinus carpio*) in the presence of titanium dioxide nanoparticles. *Chemistry and Ecology*, 33(4), 295-308.
- Marcon, L., Lopes, D. S., Munteer, A. H., Goulart, A. M. A., Leandro, M. V., & dos Anjos Benjamin, L. (2016). Pathological and histometric analysis of the gills of female *Hyphessobrycon eques* (Teleostei: Characidae) exposed to different concentrations of the insecticide Dimilin®. *Ecotoxicology and Environmental Safety*, 131, 135-142.
- Melvin, S. D. (2016). Short-term exposure to municipal wastewater influences energy, growth and swimming performance in juvenile Empire Gudgeons (*Hypseleotris compressa*). *Aquatic Toxicology*, 170, 271-278.

- Mussi, M. A., & Calcaterra, N. B. (2010). Paraquat-induced oxidative stress response during amphibian early embryonic development. *Comparative Biochemistry and Physiology Part C: Toxicology & Pharmacology*, 151(2), 240-247.
- Norhan, N. A. S., Karim, N. U., Daud, H. M., Melad, A. A. N., Zakariah, M. I., & Hassan, M. (2019). Behavioural effects of *Anabas testudineus* (Bloch 1792) towards sublethal paraquat exposure. *International Journal of Advanced Research*, 7(11), 1-7.
- Orrego, R., Milestone, C. B., Hewitt, L. M., Guchardi, J., Heid-Furley, T., Slade, A., MacLatchy, D. L., & Holdway, D. (2017). Evaluating the potential of effluent extracts from pulp and paper mills in Canada, Brazil, and New Zealand to affect fish reproduction: Estrogenic effects in fish: Estrogenic effects of pulp mill effluent extracts on fish. *Environmental Toxicology and Chemistry*, 36(6), 1547-1555.
- Palermo, F. F., Risso, W. E., Simonato, J. D., & Martinez, C. B. R. (2015). Bioaccumulation of nickel and its biochemical and genotoxic effects on juveniles of the neotropical fish *Prochilodus lineatus*. *Ecotoxicology and Environmental Safety*, 116, 19-28.
- Rosic, N., Bradbury, J., Lee, M., Baltrotsky, K., & Grace, S. (2020). The impact of pesticides on local waterways: A scoping review and method for identifying pesticides in local usage. *Environmental Science and Policy*, 106, 12-21.
- Samanta, P., Das, R., Pal, S., Mukherjee, A. K., Senapati, T., Kole, D., & Ghosh, A. R. (2018). Toxicity assessment of agrochemical Almix in *Heteropneustes fossilis* through histopathological alterations. *Interdisciplinary Toxicology*, 11(2), 138-147.
- Sharma, A., Kumar, V., Shahzad, B., Tanveer, M., Sidhu, G. P. S., Handa, N., Kohli, S. K., Yadav, P., Bali, A. S., Parihar, R. D., Dar, O. I., Singh, K., Jasrotia, S., Bakshi, P., Ramakrishnan, M., Kumar, S., Bhardwaj, R., & Thukral, A. K. (2019). Worldwide pesticide usage and its impacts on ecosystem. *SN Applied Sciences*, 1(11), 1446.
- Singh, A. K., Kumar, A., Bilal, M., & Chandra, R. (2021). Organometallic pollutants of paper mill wastewater and their toxicity assessment on Stinging catfish and sludge worm. *Environmental Technology & Innovation*, 24, 101831.
- Singh, R. N. (2012). Histopathological alterations in the kidney of *Cyprinus carpio* after exposure to dimethoate (EC 30%). *Indian Journal of Science Research*, 3(1), 5.
- Soares, P. R. L., Lucas Corrêa de Andrade, A., Pinheiro Santos, T., Caroline Barros Lucas da Silva, S., Freitas da Silva, J., Rodrigues dos Santos, A., Hugo Lima da Silva Souza, E., Magliano da Cunha, F., Wanderley Teixeira, V., Sales Cadena, M. R., Bezerra de Sá, F., Bezerra de Carvalho Júnior, L., & Gonçalves Cadena, P. (2016). Acute and chronic toxicity of the benzoylurea pesticide, lufenuron, in the fish, *Colossoma macropomum*. *Chemosphere*, 161, 412-421.
- Sribajam, S., Charoenwattanasak, S., Champasri, T., Champasri, C., & Yuangsoi, B. (2018). Toxic effects of the herbicide glyphosate on enzymes activities and histopathological changes in gill and liver tissue of freshwater fish, Silver barb (*Barbonymus gonionotus*). *Bioscience Research*, 15(2), 1251-1260.
- Stalin, A., Suganthi, P., Mathivani, S., Paray, B. A., Al-Sadoon, M. K., Gokula, V., & Musthafa, M. S. (2019). Impact of chlorpyrifos on behavior and histopathological indices in different tissues of freshwater fish *Channa punctatus* (Bloch). *Environmental Science and Pollution Research*, 26, 17623-17631.
- USEPA. (2002). *Methods for Measuring the Acute Toxicity of Effluents and Receiving Waters to Freshwater and Marine Organisms* (p. 275). United States Environmental Protection Agency.
- Wallig, M. A., & Janovitz, E. B. (2013). Morphologic manifestations of toxic

- cell injury. In *Haschek and Rousseaux's Handbook of Toxicologic Pathology* (pp. 77-105). Elsevier.
- Wang, X. H., Souders II, C. L., Zhao, Y. H., & Martyniuk, C. J. (2018). Paraquat affects mitochondrial bioenergetics, dopamine system expression, and locomotor activity in zebrafish (*Danio rerio*). *Chemosphere*, *191*, 106-117.
- Yeganeh, S., Adel, M., Ahmadvand, S., Ahmadvand, S., & Velisek, J. (2016). Toxicity of organic selenium (Selemax) and its effects on haematological and biochemical parameters and histopathological changes of common carp (*Cyprinus carpio* L., 1758). *Toxin Reviews*, *35*(3-4), 207-213.